

Case Report

Extraction of Air Gun Pellet in Lung Base Thoracic Vertebrae Region with Lateral Extracavitary Approach: A Case Report

Novan Krisno Adji^{1,4}, Komang Yunita Wiryaning Putri^{2,4}, Laksmi Indreswari^{3,4}, Muhammad Yuda Nugraha⁴, Ali Habibi⁴

1) Department of Neurosurgery, Soebandi Regional Hospital, Jember, Indonesia

2) Department of Neurology, Soebandi Regional Hospital, Jember, Indonesia

3) Department of Surgery, Soebandi Regional Hospital, Jember, Indonesia

4) Faculty of Medicine, University of Jember, Indonesia

ABSTRACT

Thoracic gunshot injuries are associated with significant morbidity and mortality, but fatal accidents from air guns are rare. Surgery in this area is challenging, especially if the gun pellet penetrates the visceral organ like the lung. In this case, we present a case of an 18-year-old male who came to the emergency department with an air gunshot (pellet) that penetrated the chest and settled in the lung base. After being shot by an air gun, the patient came with pain in the right back and weakness in both lower extremities. Based on the radiological examination, metallic corpus allienum measuring $\pm 0.8 \times 0.7$ cm has shown at the lung base as high as the Thoracic 12 vertebrae, 9.5 cm right lung laceration, right hemothorax, and emphysema subcutis on the right inferior side of hemithorax. The patient planned surgery to extract the corpus allienum through a lateral extra cavitory approach to expose the lungs at the level of the Th10-12 vertebrae. The lateral extra cavitory approach can be an alternative, less invasive method to extract foreign body lung base in front of vertebrae thoracic region.

Keywords : Air Gun, Lateral Extracavitary Approach, Thoracic Vertebrae

Correspondence : novanns21@gmail.com

INTRODUCTION

The air gun is a weapon that uses compressed air to cause the bullet to accelerate. The air gun is currently interpreted more as “toy guns” because they are considered harmless and do not have as many regulatory guidelines as real firearms (Guenther et al., 2020). The speed of air gun bullets has seriously increased in recent compressed-gas technologies, so this weapon has the potential to cause harm to humans. Air gun trauma is primarily accidental, followed by a low percentage of suicide attempts (Trsanchev et al., 2021). Thoracic gunshot injuries are associated with significant morbidity and mortality, but fatal accidents from air guns are rare (Sharma et al., 2020). In this case, we present a case

of an 18-year-old male who came to the emergency department with an air gunshot (pellet) that penetrated the chest and settled in the lung base. Surgery on this foreign area is a challenge because it is right in front of the thoracic 12 vertebrae at the bottom of the lung.

CASE REPORT

An 18-year-old male patient came to the emergency department of the RSD. dr. Soebandi with pain in the right back and weakness in both lower extremities after being shot by an air gun. The vital signs were normal. Based on anamnesis, pain in the patient's back is on a visual analog scale of 4-6. On the physical examination, *a vulnus sclopetorum* was found in the right posterior thoracic region. On muscle strength examination with a Manual Muscle Testing scale, the lower extremities show a slight decrease in muscle strength, which can only move against moderate resistance with full range of motion.

After the patient's condition was stable and through several examinations, the patient was given prophylactic drugs of ceftriaxone and tetagam to prevent possible infection. Then, the patient underwent a right lateral chest X-ray and a CT scan of the abdomen. The chest X-ray showed a corpus alienum and minimal pleural effusion (Figure 1).

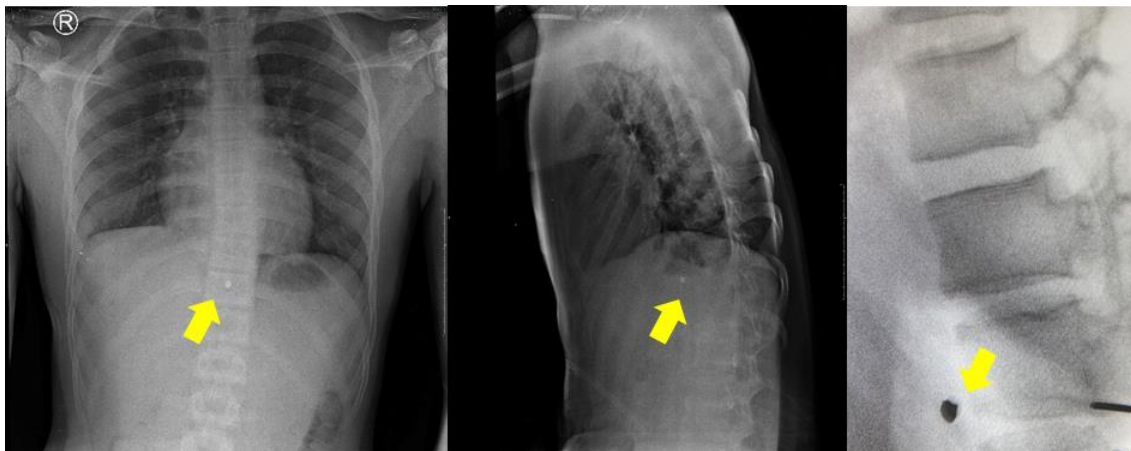


Figure 1. Anterior-posterior and lateral chest x-ray. Corpus allienum found in the thoracic 12 vertebrae region (yellow arrow)

The results of the CT scan showed the presence of a metallic corpus allienum measuring $\pm 0.8 \times 0.7$ cm at the lung base as high as the Thoracic 12 vertebrae, 9.5 cm right lung laceration, right hemothorax, and emphysema subcutis on the right inferior side of hemithorax (Figure 2).

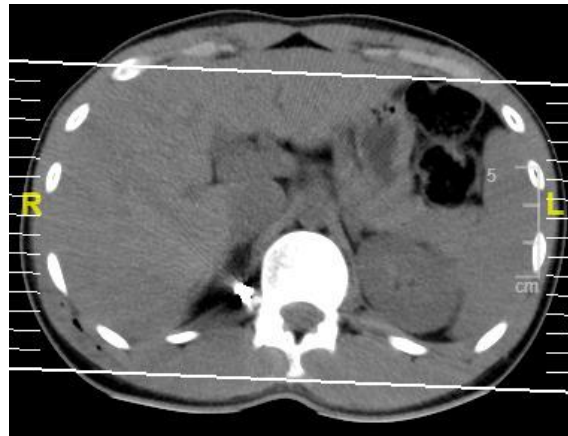

Figure 2. CT scan of thoracic vertebrae region

This surgery is a joint operation performed by a neurosurgeon. The patient planned surgery to extract the corpus allienum through a lateral extra cavitory approach to expose the lungs at the level of the Th10-12 vertebrae (Figure 3). The corpus allienum was a metal bullet at the lung base as high as the Th12 vertebrae. After removing the bullet, the patient experienced a decrease in pain scale to 1-3 on the first day after surgery. Pain continues to decrease, and there are no signs of postoperative infection.

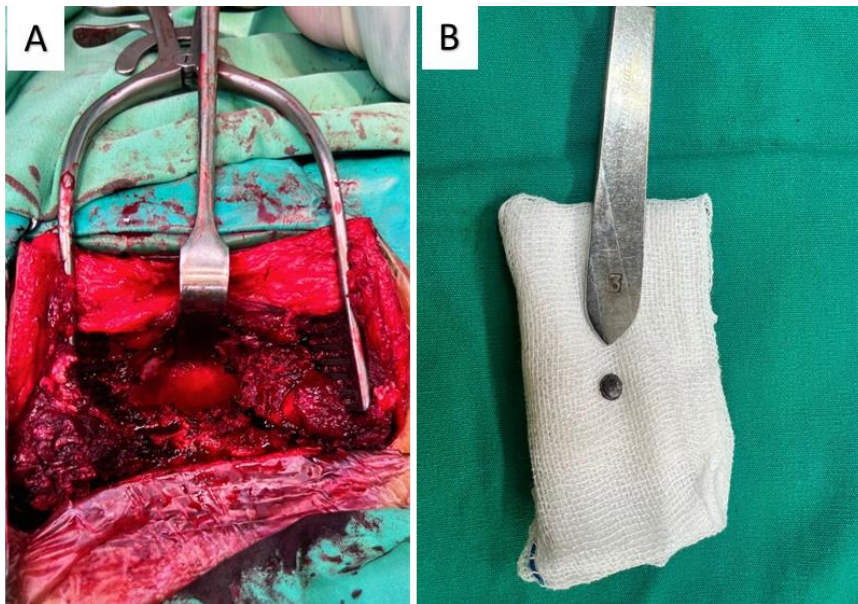


Figure 3. (A) Lateral extracavitary approach surgery patient's position. (B) Air gun pellet after extraction

DISCUSSION

A non-spherical metallic projectile designed for air guns is commonly known as an air gun pellet. These pellets exhibit distinct characteristics compared to bullets used in conventional firearms, particularly regarding the pressures they encounter (Alakhfash et

al., 2020). Typically, air gun pellets have diameters within the range of 4.5 mm to 6 mm and possess a mass of approximately 0.2 grams (Jafroodifar et al., 2020). Achieving a critical projectile velocity of 70 m/s is essential for these pellets to penetrate human skin (Dumenčić et al., 2020). Depending on the type of air gun employed, whether spring-powered or pneumatic, the projectile's velocity can span from 82.5 m/s to 136 m/s. In contrast, bullets fired from firearms travel at significantly higher velocities, starting at a minimum of 227 m/s (Jafroodifar et al., 2020).

Injuries resulting from air guns can exhibit significant variation depending on factors such as the specific body area affected, the type of air gun employed, the shooting distance, and the age of the injured individual. In the context of Air gun pellet injuries, roughly 24.1% manifest as puncture wounds (Jafroodifar et al., 2020). The range of injuries caused by these pellets spans from minor skin abrasions to severe and potentially life-threatening conditions, like lung lacerations and contusions. Air guns can potentially harm air-filled organs like the lungs, which occupy a substantial portion of the chest cavity and lie close to the chest wall. Thoracic injuries, as a whole, rank as the third most common form of trauma, following head and extremity injuries. Thoracic trauma is associated with high morbidity and mortality, accounting for approximately 25% of trauma-related deaths, second only to head trauma. The most prevalent pattern of lung injury is pneumothorax, followed by pulmonary hemorrhage, in contrast to contusion typically seen in cases of blunt trauma. This pattern can be attributed to the significant kinetic energy of pellets, resulting in the disruption of the lung's pleural interface and propagation through the lung tissue, often causing disruptions at the capillary-alveolar interface. Due to their relatively small size, pellets rarely cause extensive trouble in the capillary-alveolar interface, which is why contusion is a less common injury pattern resulting from pellet impacts (Rafiq et al., 2019)

While there is a consensus on retrieving projectile foreign bodies, most authors advocate for a conservative approach in asymptomatic cases and emphasize the importance of thorough clinical evaluation to determine the necessity of removal. The decision to remove or leave the pellet in place is controversial (Zaher, 2022). Surgical intervention and exploration were historically considered to offer the most comprehensive assessment of injuries, foreign body removal, hemorrhage control, and the excision of damaged lung tissue (Aljehani et al., 2019). However, our decision to proceed with surgery is driven by the desire to proactively prevent potential complications in the future, including infection, migration, pain, tissue reactions, and interference with future imaging procedures like MRI. Prolonged residence of foreign bodies within soft tissues can lead to scarring, rendering removal more challenging (Rothermund et al., 2018).

Surgical procedures to remove foreign bodies should be performed using appropriate techniques to minimize complications (Secer et al., 2014). Minimally Invasive Techniques (MIT) such as microscopy, stereotaxy, endoscopy, and neuro-navigation have been reported as potential options for removing foreign objects from the vertebral region. However, their implementation can be challenging in cases where medical facilities need

more resources and facilities (Alzhrani et al., 2015). So, another surgical method is needed to overcome this problem, and we proposed The Lateral Extracavitary Approach (LECA). The lateral extracavitary approach (LECA) to the thoracolumbar spine, initially introduced by Larson et al. in 1976 for addressing traumatic conditions, offers a surgical method that grants both dorsal and ventrolateral access to the thoracolumbar spine. Importantly, it avoids the potential complications associated with conventional transpleural and transperitoneal approaches. LECA can be the alternative method that less invasive and has minimal complications, The LECA has become a well-established choice for addressing an array of ventral and ventrolateral pathologies affecting the thoracolumbar spine (Foreman et al., 2016). In this case, we employed the lateral extracavitary approach for foreign body extraction, a relatively uncommon method for addressing foreign bodies located in the lung base region. It's important to note that the lateral extra-cavitary approach is challenging. As demonstrated in this study, the most frequent complications are related to the approach and tend to involve pulmonary issues, although many of these complications are asymptomatic, such as reactive pleural effusion. These findings align with recent reports in the medical literature (Hartmann et al., 2018).

CONCLUSION

The management of projectile foreign bodies, particularly in cases involving air gun pellets, involves a careful decision-making process. There is a prevailing consensus among experts to adopt a conservative approach for asymptomatic cases and prioritize thorough clinical evaluation to determine the necessity of removal. If the removal is needed, the lateral extra cavitory approach can be an alternative method that is less invasive to extract foreign body lung base in front of vertebrae thoracic region.

REFERENCES

- Alakhfash, A. A., Alqwaee, A., & Almesned, A. (2020). Percutaneous removal of air-bullet gunshot: case report and literature review. *The Egyptian Heart Journal: (EHJ): official bulletin of the Egyptian Society of Cardiology*, 72(1), 21. <https://doi.org/10.1186/s43044-020-00055-3>
- Aljehani, Y., Alsafwani, E., & Alayyaf, N. (2019). A novel approach in retrieving retained pulmonary bullet injury. *Trauma case reports*, 21, 100191. <https://doi.org/10.1016/j.tcr.2019.100191>
- Alzhrani, G. A., Alturki, A. Y., & Almusrea, K. N. (2015). Removal of lumber spine foreign body using minimal access system with navigation. *Asian journal of neurosurgery*, 10(2), 108–110. <https://doi.org/10.4103/1793-5482.145160>

- Dumenčić, B., Rajc, J., Pavoković, D., & Damjanović, T. (2020). Fatal injury by air gun: A case report. *Egyptian Journal of Forensic Sciences*, 10(1). <https://doi.org/10.1186/s41935-020-00182-7>
- Foreman, P. M., Naftel, R. P., Moore, T. A., 2nd, & Hadley, M. N. (2016). The lateral extracavitary approach to the thoracolumbar spine: a case series and systematic review. *Journal of neurosurgery. Spine*, 24(4), 570–579. <https://doi.org/10.3171/2015.6.SPINE15169>
- Guenther, T., Chen, S., Wozniak, C., & Leshikar, D. (2020). Fatal cardiac injury sustained from an air gun: Case report with review of the literature. *International journal of surgery case reports*, 70, 133–136. <https://doi.org/10.1016/j.ijscr.2020.04.039>
- Hartmann, S., Wipplinger, C., Tschugg, A., Kavakebi, P., Örley, A., Girod, P. P., & Thomé, C. (2018). Thoracic corpectomy for neoplastic vertebral bodies using a navigated lateral extracavitary approach-a single-center consecutive case series: technique and analysis. *Neurosurgical review*, 41(2), 575–583. <https://doi.org/10.1007/s10143-017-0895-z>
- Jafroodifar, A., Thibodeau, R., Goel, A., & Hanumaiah, R. (2020). Wandering intravascular air gun BB pellet. *Radiology case reports*, 15(12), 2627–2631. <https://doi.org/10.1016/j.radcr.2020.09.055>
- Rafiq, S., Shafi, F., Sangeen, A., & Rehman, S. (2019). Lung Injuries on Computerized Tomography Due to Pellet Gun. *Galician Medical Journal*, 26(2). <https://doi.org/10.21802/gmj.2019.2.4>
- Rothermund, J. L., Rabe, A. J., Zumberge, N. A., Murakami, J. W., Warren, P. S., & Hogan, M. J. (2018). Image-guided percutaneous removal of ballistic foreign bodies secondary to air gun injuries. *Pediatric radiology*, 48(1), 120–123. <https://doi.org/10.1007/s00247-017-3977-8>
- Secer, M., Ulutas, M., Yayla, E., & Cinar, K. (2014). Upper cervical spinal cord gunshot injury without bone destruction. *International journal of surgery case reports*, 5(3), 149–151. <https://doi.org/10.1016/j.ijscr.2014.01.009>
- Sharma, R., Chaturvedi, V., Jangid, N., & Ojha, S. (2020). Air gun bullet related lung injury. *Pediatric Oncall*, 17(4). <https://doi.org/10.7199/ped.oncall.2020.40>
- Tsranchev, I., Timonov, P., & Alexandrov, A. (2021). Penetrating Brain Trauma due to Air Gun Shot - a Case Report. *Folia medica*, 63(6), 977–980. <https://doi.org/10.3897/folmed.63.e59428>
- Zaher, Z. (2022). Rescue of a Child with Fatal Cardiothoracic Injuries from an Air Gun: A Case Report. *The Egyptian Cardiothoracic Surgeon*, 4(4), 64 - 67. <https://doi.org/10.35810/ects.v4i4.230>